



**International Scientific Committee of Ozone Therapy
ISCO3**

Ozone in Non-Rheumatic Locomotor System Pathologies

Approved by ISCO3 on July 11, 2014

Drafters of the paper

Dr. Alberto Alexandre

Neurosurgeon. European Neurosurgical Institute – Treviso, Italy. Member of ISCO3 (International Scientific Committee of Ozone Therapy).

Dr. José Baeza

Trauma and Orthopaedic Surgery. Hospital Virgen del Consuelo – Valencia, Spain. Member of ISCO3 (International Scientific Committee of Ozone Therapy).

+ Dr. Vijail Sheel Kumar

Neurosurgeon. Dr Kares Hospital – Gurgaon-Delhi, India. Member of ISCO3 (International Scientific Committee of Ozone Therapy). Passed away in 2012.

Suggestion on how to cite this paper:

ISCO3 - International Scientific Committee of Ozone Therapy. (Madrid, 2014).
Ozone in Non-Rheumatic Locomotor System Pathologies. www.isco3.org

Contact for correspondence: ISCO3 Secretariat: Email: info@isco3.org



Ozone in Non-Rheumatic Locomotor System Pathologies

INDEX

Introduction	3
Experimental approach	3
Basic advices	4
Tendinopathies and enthesistis	5
Osteoarthritis	6
Nerve entrapments	7
Spine pathology	7
a) Disc-radicular conflict.	
b) Degenerative disc disease (DDD)	
c) Grade I symptomatic spondylolisthesis	
d) Spondylopathy	
e) Facet joint disease	
f) Facet joint osteoarthritis	
g) Lumbar spinal stenosis	
Conclusion remarks	14
References	15



Ozone in Non-Rheumatic Locomotor System Pathologies

INTRODUCTION

Although bone and joint diseases were not one of the first indications of ozone therapy, after Dr Verga's (1) and Dr Riva Sanseverino's papers (2), several following publications (3–7) encouraged doctors to use ozone for treating these kind of pathologies. Unfortunately, the first publication on this pathology (8), more than 30 years before Dr Verga's one, remained unnoticed.

Results have been so positive that nowadays the majority of papers about ozone therapy are related to these problems and the highest level of evidence on ozone therapy effectiveness is also related to them. According to the systematic review and meta-analysis of Magalhaes et al (9), for low back pain:

- paravertebral ozone therapy has a level of evidence II-1 (Evidence obtained from systematic review of randomized trials or several randomized clinical trials) with grade of recommendation IB (strong recommendation, with moderate quality evidence), and
- intradiscal ozone therapy has a level of evidence II-3 (evidence obtained from multiple time series or dramatic results in uncontrolled trials) with grade of recommendation IC (strong recommendation, low-quality evidence)

In this document, the authors will show the rationale of using ozone in these diseases and what we can expect from it, based on publications and their own experience in the past two decades.

EXPERIMENTAL APPROACH

The development of ozone therapy has been based on empirical science, so basic investigation to determine the best dose and protocols of administration was performed after clinical use showed the optimal dosing in a non-controlled environment. The first work about this (10) was carried out in mice pads using an standard inflammatory model with capsaicin, that proved 20 µg/mL to be the best anti-inflammatory dose for soft tissue pathology used as local injections.

This optimal concentration has been confirmed by Dr Iliakis's publications (11) as being, not only effective but also safe (12) for the tissues. Late works by Prof. Yu Bin (13) prove that



one week injection of ozone at 20 $\mu\text{g}/\text{mL}$ was the most anti-inflammatory dosing compared with 10, 30 and 40 $\mu\text{g}/\text{mL}$ in rabbit model.

We need more animal investigation and more controlled studies in human to narrow the wide therapeutic approach of ozone therapy in musculoskeletal pathologies, but we have a rationale start point in the above publications, that also support the most widely used protocols for treating these diseases. Regarding disc-radicular conflict (CDR), the experimental investigation in animals has been more deeply developed, using models with rabbit (14,15), dog(16–18), lamb(19) and pig(20,21). Even some publications (22–24) show histological changes after ozone administration in humans with unsuccessful result submitted to surgery. These studies have provided confirmation of empirical use of ozone for disc diseases and have improved dosing and safety (25,26).

Many other clinical controlled and non-controlled studies have been published in the last 15 years showing us the way to treat spine diseases, but only latest papers (9,27,28) prove with high evidence level the effectiveness and safety of ozone injections to treat CDR.

We will try to summarize this information and offer an evidence based guideline for these groups of pathologies. The reader must notice that except for disc herniation, the studies on other indications have a low level of evidence, so the use of ozone should be done on a compassionate basis, when standard well documented treatments have failed, are not applicable to the patient or the patients resign to them. We advice to use official informed consent from the scientific associations are they are usually lex-artis based and formally reviewed by a lawyer.

BASIC ADVICES

Many doctors believe that strict aseptic measures are not necessary as ozone is a strong antiseptic. This is absolutely false (29), as ozone is quickly tampered by antioxidant substances in the plasma and interstitial water. Moreover, many bacteria have antioxidant defenses against oxidant molecules. For this reason, strict aseptic measures should be used for preparing ozone injections.

Optimal dosing is not always optimal for all patients. Our advice is to start with slightly lower dosing and rise to the optimal after one-two injections (30). Higher doses are more painful than lower ones. Some patients can benefit from a slight higher dose. Please inject slowly, to avoid pain if possible. Protocols are not absolutely rigid. They can be adapted to each patient's needs, but we recommend not changing the frequency of injections until some improvement has been reached.



As ozone is a gas, we advise to use the thinnest needle possible (27G / 30G), to diminish the injection pain. Local anesthetics can be used, although topic anesthesia or even cryotherapy can be useful to avoid the pain produced by the injection. The ozone itself produces some degree of pain due to the radicals produced by the first chemical reactions. Some authors believe this pain is useful as it induces plasticity in the Central Nervous System, needed to control pain (29). Others disagree, as clinical results are also good using local anesthesia in the point of injection prior to ozone injection (31). There is no publication up to now proving any of the controversial ideas. We even don't know if ozone can degrade these substances *in vivo* (or *in vitro*). Syringes should be ozone-proof; standard low-pressure syringes are siliconized, so they can be used for a single injection, as repeated use in the same patient can degrade silicone and produce plastic particles.

Glass syringes are optimal, but they are unpractical, as they need a re-sterilization. Latex gloves can be used if there is low chance to produce ozone leak during the injection. Otherwise, vinyl gloves are better, as they are ozone-proof. Local infection close to the point of injection is a formal contraindication. Use of anti-platelets or anticoagulants is a formal contraindication when we inject into a cavity or a virtual space and INR is equal or above 3. In these patients, the use of low-molecular-weight heparins is advised (32). General ozone therapy contraindications apply in all cases. This is not an infiltration manual, so technical description will be focused on ozone therapy related details of the injection procedure.

TENDINOPATHIES AND ENTHESITIS

Due to its anti-inflammatory effects and the lack of significant side effects, ozone can be used instead of steroids for local injections where we usually use them. It has been tried with success in shoulder tendinopathies (33–35), tennis-elbow (36), D'Quervain's tendinitis (37), trochanteric hip bursitis (35), and others. Global good results for these pathologies are 80% (33–37). Calcifications are not a contraindication (38).

Use the thinnest and more suitable needle for the injection. Start with 10 µg/mL and rise to 20 in the second or third injection if possible. Remain at 20 µg/mL or even 25 if the pain of injection is low. Amount of ozone depends on the target to treat. Small tendons can be injected peritendon with 2-3 mL. Shoulder tendons can be injected with 5-10 mL depending on the tendons affected.

Trochanteric bursae can be injected with even 15 mL in big patients, In these patients, injecting along the ilio-tibial band may be useful if painful; look for painful points along the band and inject 2-3 mL per point. Careful examination of the patient should be performed to determine the points of injection before each session, as painful points may change, as usually more than one anatomical structure are involved in the process.



The protocol should be adapted to patient evolution. Injections should be performed on a weekly basis up to a number of 3-5. If there is no improvement after this time, treatment should be stopped. Total number can be higher, as injections can be done weekly meanwhile there is a clinical improvement. You will usually not need more than 6-8 injections to achieve a significant pain reduction (35). There is no need to go further, as the patient keep on improving during a month or more after the last injection. Some doctors inject twice a week but there is no benefit for the patient, as the treatment is not shortened in time and final number of injections is bigger (39).

Other treatments combined with ozone have shown to be useful, as physiotherapy (40), hyaluronic acid injections (37) or shock waves (38). We usually don't overlap other treatments, to clearly know which the effect of ozone is. Heat in the point of injection should be avoided at least for 48 h as CT controls of para-vertebral muscle injections show presence of gas up to this period (41) and deep heat can produce gas volume to increase and produce pain.

OSTEOARTHRITIS

Ozone injections have also widely used to treat knee osteoarthritis (6,7,42–54). There are few references to other locations, as hip (39,53–56), shoulder or ankle. Severe osteoarthritis has been shown not to be a contraindication; these patients improve almost the same as low grade osteoarthritis but the time free of symptoms is significantly shorter (53). Based on a rationale approach, severe deformities and misalignment can be considered as contraindications, unless no other option of treatment is available for the patient.

General dosing of the previous chapter apply for these patients. Amount of ozone per injection depends on the size of the joint and their compliance, using 10-15 mL for knee or shoulder, 5-8 for hip or ankle. Approach is well described in infiltration manuals (32). Careful exploration before each injection should be carried out, as in many cases the intrarticular disease has periarticular pathology, in form of enthesitis, bursitis or tendinitis. If these periarticular points are not treated with ozone or other complementary treatments, full success will not happen.

For periarticular injections, please follow the instructions in the proper chapter. Injections should be done on a weekly basis to avoid overdose, as referred in the previous chapter (44). Following this advices, good results range from 74% (35) to 80% (53). Other treatments can be used together or after ozone injections. For periarticular injections we should respect the 48h window period. Intrarticular injections of hyaluronic acid (35) and rich-platelet plasma(57,58) are being used together with ozone with encouraging results.



NERVE ENTRAPMENTS

There are few publications (34,35,59) about the use of ozone injections in peripheral nerve entrapments as carpal tunnel or cubital tunnel syndrome. Although the basic physiopathology is the same of the pathologies in the previous chapters, neural tissue is more sensible to ozone, so lower doses must be used to reach a good result (60).

For carpal tunnel syndrome, the injection should be performed carefully perineurally with concentration of 5-7 µg/mL and amounts of 3-5 mL. This dosing is, on a weekly basis, enough to get good results in near 80% of the patients. Papers on this topic are so scarce that we cannot assess which kind or severity is a contraindication. We advise to treat patients without severe motor deficit and non-progressive symptoms, but this is a rationale advice not based in any evidence.

SPINE PATHOLOGY

This pathology has been left to the end on purpose, as all the concepts shown in the previous chapters are true for spine diseases susceptible for ozone treatment and should be carefully evaluated and applied (61).

General indications for ozone treatment are:

- Disc herniation or disc-radicular conflict (CDR) as we prefer to define
- Degenerative disc disease (DDD)
- Grade I symptomatic spondylolisthesis
- Spondylopathy
- Facet joint disease
- Facet joint osteoarthritis
- Lumbar spinal stenosis

The reader must have a deep knowledge on these pathologies and should know how to solve the possible complications of the use of ozone on them to guaranty the quality of the treatment and reach the highest level of success. Otherwise, he will not understand many

points in this chapter, as explaining in detail the physiopathology of these pathologies is not the aim of this paper.

We have to remember what has been explained in previous sections of this text. It is usually needed to treat satellite points of pain, especially in cervical pathology, where there are very common in the form of mio-fascial syndromes. In these cases, we can inject ozone in the points of pain in small amount (2-3 mL) at 10-15 $\mu\text{g}/\text{mL}$ or treat with others pain techniques.

Regarding techniques and procedures, there are two main ways of treatment for these pathologies.

The first one is the paravertebral approach. It was first described by Dr Verga(1) as a protocol used by him and his team named “Discosan” for treating lumbar disc herniation. The problem found after some years were the number of sessions of infiltrations was well above 15, so the length of the treatment (3 months) made some patients abandon the treatment. To avoid this, Dr Scuccimarra (62), member of Dr Verga's team, developed the “deep paravertebral injections”, actually perifacet joint injections. This technique shortened considerably the number of sessions reducing them to 10 and up to a maximum of 15. Both techniques are basically para-spinal injections.

The classical paravertebral approach is done locating the upper part of the spinous process of the superior vertebrae involved in the CDR and injecting 2,5 cm to the left and right of the spinous process with a 0,8 x 40 mm needle an amount of 5-10 mL per point depending on the size of the patient. Some authors (63) have proved that using lower ozone concentration (10 $\mu\text{g}/\text{mL}$) can be as useful as standard concentration (20 $\mu\text{g}/\text{mL}$). Our advice is to use a 0,4 x 40 mm needle or thinner if available. Local, topic anesthesia or cryotherapy can be used to reduce the pain of the needle. Injection should be done slowly. Using local anesthesia in the muscle can reduce the effect of ozone injection. The “deep paravertebral injection” uses a similar procedure, but the distance from the middle line is narrower (1,5 cm for cervical and dorsal injection and 2 cm for lumbar injection) and it is necessary using longer needles (0,4 or 0,5 x 90 mm spinal needle) to be able to locate the posterior joints with the tip of the needle an inject periarticularly. The amount of ozone used is the same.

It is also possible to inject over the laminae, close to the foramen, instead of around the facet joints, but risk of accidental dura or radicular puncture is greater (although without permanent side effects); this can be done for nerve root de-inflammation. Dr Verga (64) modified his technique for cervical and dorsal disc herniation, narrowing the distance from the spinous process to 1,5 cm left and right, using shorter needles (25 or 30 mm) and decreasing the ozone volume per point to 3-7 mL. Dorsal approach uses the same technique as for cervical paravertebral injections.

Fig 1: Classical paravertebral injections

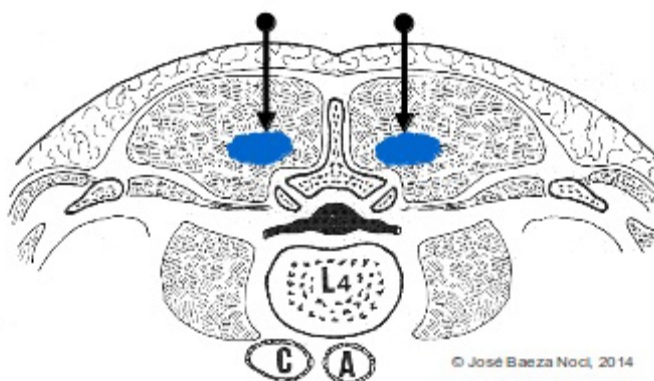
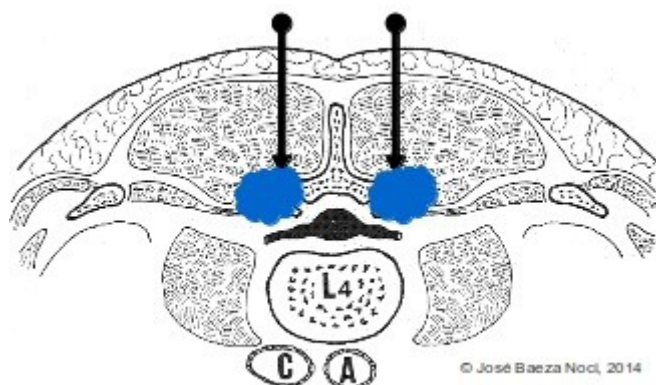


Fig 2: Deep paravertebral injections



The second approach is the intradiscal – intraforaminal one (65). The idea (66) was taken from the chemonucleolysis with chemopapain, so the injection procedure has been inherited



from it. Ozone has proved to induce dehydration in nucleus pulposus material(22,23), so the intradiscal injection can help to alleviate the root compression(67). Moreover the ozone well proved anti-inflammatory effect can help to diminish disc, root, ganglia and periradicular tissue inflammation (67).

To obtain this combination of mechanical and biochemical effects, ozone should be injected intradiscal and intraforaminal in all cases, injecting around the affected root (68). Although in many cases we can see in the fluoroscope not only the gas discography but a gas leakage to epidural and periradicular space, this gas is oxygen with some molecules of ozone (or none) as the majority react immediately around the injection point; this is why we recommend to use both procedures when you want to get both mechanical and biochemical effect. The technique is well described in many manuals so we will center on technical details related to ozone therapy.

We, as always, advice to use thin needles, as the 22G x 11” Chiba needle for both procedures in lumbar disc. For cervical disc, 25G x 3½” is a good choice for intradiscal injection; for intraforaminal injection we advice to use pen tip needle – same size - to avoid accidental root, medulla or vertebral artery puncture. Imaging guidance is mandatory: CT or fluoroscope. Local anesthesia is mandatory for lumbar disc, as in some cases we need to change the needle position and we avoid pain in this situation. Sedation is optional, as some authors don't use it, but the authors advice using a light sedation to make this procedure more comfortable for the patient and the doctor.

After reviewing many publications, not only the animal investigation papers, but the clinical reviews, intradiscal concentration can range from 25 µg/mL (23,69,70) to 40 µg/mL (71–74); greater concentrations produce better results (72,75,76). Some authors from China (76) even use 50 or 60 µg/mL, but all animals models have shown annulus disruption secondary to concentrations of 50 µg/mL or more (20), so we advice not using concentrations over 40 µg/mL.

Ozone volume for intradiscal cervical injection (24,77) should be 1-2 mL and for lumbar disc, 5-7 mL(65). Intraforaminal approach for requires 5 mL volume for cervical injection and 15 mL for lumbar injection(65,69,70,78–80). Dorsal approach, as in cervical paravertebral technique, is quite less frequent. In thin patients, the cervical needle can be used; for bigger patients, the lumbar Chiba needle is a good choice. Ozone volumes are for intradiscal are 2-3 mL and for intraforaminal, 7-10 mL.

ISCO3

Avenida Juan Andrés 60, local 1 bajo
(+34)669685429
28035, Madrid (Spain)

10

Tel/Fax (+34) 913515175
Mobile

info@isco3.org
www.isco3.org

Fig 3: Intradiscal injection

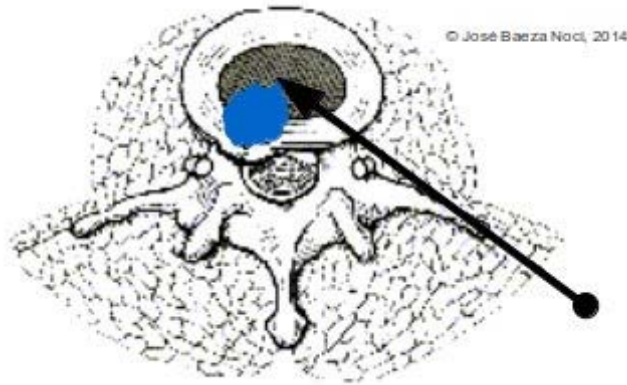
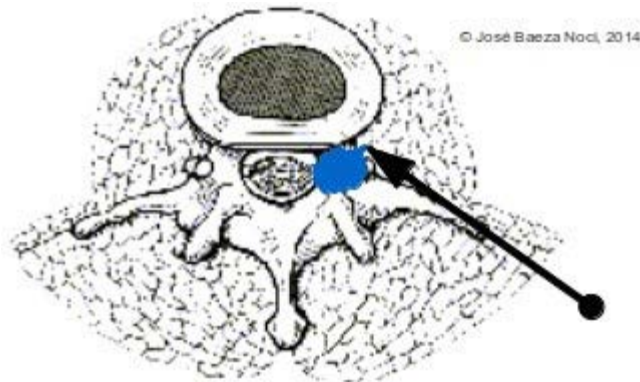


Fig 4: Intraforaminal injection





For lumbar radiculopathy, Dr Mattozzi(81) proposed caudal epidural ozone injections with standard pen tip needle and introducer, usually 27G x 3½”, with 20 mL of ozone at 20 µg/mL each two weeks up to 4-5 times. There are few publications on this(82), but authors' personal experience is promising and it is under heavy investigation.

a) Disc-radicular conflict

In these patients, the problem is centered on the CDR problem. The indication for treatment is the same as for surgery (68), so in case of severe neurological symptoms we prefer to start with intradiscal-intraforaminal approach (44,65,83–86), unless there is a contraindication (annulus calcification or spondylosis). A couple of days after, we proceed with paravertebral injections, twice a week up to six or eight. Depending on the spine pain, or the presence of facet joint pain, the technique can be classical or “deep”. For strong neurological symptoms, deep perforaminal injections can be used.

In patients with more spine pain than radicular pain, paravertebral technique can be used twice a week. If after 4-5 session there is no improvement, intradiscal-intraforaminal technique should be used. Otherwise, paravertebral can be kept on up to 10-12 sessions. No further should we go if there is no improvement. In these cases, we should recheck the patient.

b) Degenerative disc disease (DDD)

It is difficult to reach this diagnose, because patients with DDD usually have spondylosis or facet joint problems. Isolated DDD can only be diagnosed by discomanometry. Use of ozone in this pathology is not well documented. Author's opinion is using intraforaminal approach, repeated if needs 2 or 3 times each 2 weeks. Deep paravertebral injections twice a week up to 10-12 session is an option. However, there is no bibliography to support this as DDD is not a frequent diagnose.

In case of concomitant pathology, these should be treated as indicated in the next chapters.

c) Grade I symptomatic spondylolisthesis

The only papers about this are the ones from Dr. Bonetti (87,88). He used CT guided injection into pars articularis of 2-3 mL of ozone at 20 µg/mL, one or two times. Results are maintained at least for one year.

d) Spondylopathy

ISCO3

Avenida Juan Andrés 60, local 1 bajo
(+34)669685429
28035, Madrid (Spain)

12

Tel/Fax (+34) 913515175
Mobile

info@isco3.org
www.isco3.org



Treating degenerative spine is a growing indication of spinal ozone therapy (89–92). There are few publications about this, but the number is increasing. Cervical and lumbar spondylosis are frequently related with facet joint osteoarthritis; dorsal spondylosis is usually isolated because ribs protection factor.

As commented before, concomitant pathology should be also treated. These patients usually only suffer from spine pain, so we use classic paravertebral injections together with perifacet joint injections in case of facet problem, usually present for cervical and lumbar spine. Ten sessions twice a week and then go on with 2-5 more sessions, once a week. It is usually a long treatment so is better to warn the patient before starting to avoid treatment abandon.

Some authors prefer to use CT-guided facet joint injections instead of deep paravertebral ones. It depends on availability and cost. Technical details are the same as for spondylolisthesis. In case of radicular pain others diagnoses should be considered, as facet joint cyst or lumbar spinal stenosis.

e) Facet joint disease

There is no reference published about this. Mechanical factors should be corrected first. Afterwards, in case of persistent pain and failure of other conservative treatments, classical paraveterbral or deep perifacet joint injections procedure can be used, twice a week up to 10-12 sessions. CT-guidance injections are an option, as treatment can be shortened theoretically, but with an increase in cost.

f) Facet joint osteoarthritis

Few references are found in bibliography about this indication, usually related with spondylopathy.

As in the former chapter, the choices are classical paravebral, deep perifacet joint or CT-guided facet joint injections. The first one is the least ethiological treatment and the last one is the optimal, if cost is not a problem. We don't have enough evidence to advice one over the rest.

g) Lumbar spinal stenosis

Only a couple of papers have been published on this topic (90,93). Approach can be done through 3-4 intraforaminal + perifacet joint CT-guidance injections or through deep paravertebral injections. The first choice is more expensive, technical demanding but short in time. The second is simpler but more time consuming and takes more time to finish the treatment. Results published are similar for both techniques.

ISCO3

Avenida Juan Andrés 60, local 1 bajo
(+34)669685429
28035, Madrid (Spain)

13

Tel/Fax (+34) 913515175
Mobile

info@isco3.org
www.isco3.org



Epidural ozone injection through sacrum hole together with perifacet joint injection without direct imaging guidance is under evaluation and preliminary reports are promising.

CONCLUSION REMARKS

Non-rheumatic locomotor system pathologies are nowadays the more scientifically supported indication for ozone therapy.

It is a safe and effective treatment that is resisting any comparison published. Moreover, the cost of the treatment is cheap so it is likely that a cost-effective study could prove that it is one of the best treatments for these pathologies, even better than systemic drugs treatment.

Side effects are small and always related to defective technique, so it is mandatory to be well trained to perform these approaches.

More clinical trials are needed to achieve a higher level of evidence in non-spine indications.

REFERENCES

1. Verga C. Nuovo approccio terapeutico alle ernie e protusioni discali lombari. *Rivista Di Neuroradiologia*. 1989;(2):148.
2. Riva Sanseverino, E. [Knee joint disorders treated by oxigen-ozone therapy]. *Europa Medicophysica*. 1989;3(25):163–70.
3. Escarpenter J, Valdes O. Resultados terapéuticos en la osteoartritis de la rodilla con infiltraciones de ozono. *Revista Cubana de Investigación Biomédica*. 1997;(16):124–32.
4. Gheza G, Ipprio L, Bissolotti L. [Oxygen-Ozone Therapy in a Diabetic Patient with De Quervain's Tenosynovitis Associated with Joint Arthrosis]. *Riv Ital Ossigeno-Ozonoterapia*. 2002;1(2):189–92.
5. Gaffuri M, Garaffo R, Gheza G. [Oxygen-Ozone Therapy for Lateral Humeral Epicondylitis: Preliminary Findings]. *Riv Ital Ossigeno-Ozonoterapia*. 2003;2(2):169–72.
6. Gheza G, Bissolotti L. [Intra-articular Oxygen-Ozone Injection for Knee Disease Proposed Guidelines]. *Riv Ital Ossigeno-Ozonoterapia*. 2003;2(1):63–6.
7. Moretti B, Lanzisera R, Morese A, Moretti L, Patella S, Patella V, et al. [O2-O3 vs Chondroprotectors in the Treatment of Osteoarthritis of the Knee]. *Riv Ital Ossigeno-Ozonoterapia*. 2004;3(1):65–72.
8. Pribluda S. [treatment of Lumbosciatica and Other Similar Syndromes with Subcutaneous Ozone.]. *Sem Med*. September 26, 1963;123:1026–8.
9. Magalhaes FNDO, Dotta L, Sasse A, Teixeira MJ, Fonoff ET. Ozone therapy as a treatment for low back pain secondary to herniated disc: a systematic review and meta-analysis of randomized controlled trials. *Pain Physician*. April 2012;15(2):E115–129.
10. Ceccherelli F, Gagliardi G, Faggian L, Loprete F, Giron G. Analgesic effect of subcutaneous administration of oxygen-ozone. A blind study in the rat on the modulation of the capsaicin-induced edema. *Acupunct Electrother Res*. 1998;23(3-4):171–84.
11. Iliakis EM, Valadakis V, Vynios D, Tsiganos C, Agapitos E. Rationalization of the activity of medical ozone on intervertebral disc; a histological and biochemical study. *Rivista di Neuroradiologia*. 2001;(14 supl 1):23–30.
12. Iliakis E, Petropoulos I, Iliaki A, Agapitos E, Agrogiannis G. Is Medical Ozone Safe when Injected Intra-articularly? *International Journal of Ozone Therapy*. 2008;7:000–000.

13. Yu Bin. [Ozone treatment in osteoarthritis; basic and clinical investigation]. Proceedings of the IV Meeting of the CFOT [Internet]. Shenyang; 2012. Retrieved from: http://www.cfot.org.cn/news_view.asp?id=364
14. Kim Y, Jeon B, Kwon K. [Ozone Chemonucleolysis on the Lumbar Intervertebral Disc of the Rabbit]. *J Korean Neurosurg Soc.* 2003;34(6):570–4.
15. Li S, Yu G, Chen G. [Impact of different concentrations of ozone injection on pathological changes of rabbit skeletal muscle]. *J Modern Clin Med Bioeng* [Internet]. 2006;(6). Retrieved from: http://en.cnki.com.cn/Article_en/CJFDTOTAL-XDLC200606012.htm
16. Castrini A, Prignacca E. [Treatment Protocol for Herniated Disc with Oxygen-Ozone Therapy in Dog]. *Riv Ital Ossigeno-Ozonoterapia.* 2002;1(1):113–5.
17. Yu Z, He X, Chen Y. [Influence of ozone on the ultrastructures of nucleus pulposus]. *J Intervent Radiol* [Internet]. 2001;(3). Retrieved from: http://en.cnki.com.cn/Article_en/CJFDTOTAL-JRFS200103017.htm
18. Yu Z, He X, Chen Y, Zeng Q, Liu C, Zhao Z, et al. [Percutaneous intradiscal ozone (O₃)-injection:an experimental study in canines]. *Chin J Radiol* [Internet]. 2002;50(4). Retrieved from: http://en.cnki.com.cn/Article_en/CJFDTOTAL-ZHGS200204023.htm
19. Algara C, Garcia O. Oxygen-ozone percutaneous nucleolysis: an animal model study. Proceedings of the 1st world congress on minimally spine surgery. Honolulu; 2008.
20. Muto M. [Intradiscal and Intramuscular Injection of Oxygen-Ozone: Pathological Evaluation. Work in Progress]. *Riv Ital Ossigeno-Ozonoterapia.* 2004;3(1):7–13.
21. Tian J, Zhang jin-shan, Xiao Y, Liu J, Yang B, Li J, et al. [Oxidative effect of different concentration of ozone injected into porcine normal lumbar disks]. *Chin J Intervent Imaging Ther* [Internet]. 2007;(4). Retrieved from: http://en.cnki.com.cn/Article_en/CJFDTOTAL-JRYX200704018.htm
22. Alexandre A, Buric J, Paradiso R, Salgado H, Murga M, Corò L, et al. Intradiscal injection of O₂-O₃ to treat lumbar disc herniations. *Riv Ital Ossigeno-Ozonoterapia.* 2002;1(2):165–9.
23. Andreula C, Muto M, Leonardi M. Interventional spinal procedures. *Eur J Radiol.* May 2004;50(2):112–9.
24. Alexandre A, Corò L, Azuelos A, Buric J, Salgado H, Murga M, et al. Intradiscal injection of oxygen-ozone gas mixture for the treatment of cervical disc herniations. *Acta Neurochir Suppl.* 2005;92:79–82.

25. Tian JL, Zhang JS, Xiao YY, Liu JT, Yang B, Li JK, et al. Changes of CSF and spinal pathomorphology after high-concentration ozone injection into the subarachnoid space: an experimental study in pigs. *AJNR Am J Neuroradiol*. July 2007;28(6):1051–4.
26. Yu B, Lin Q-R, Wang B-W, Zhu Q, He X-F. Effect of Intra-Articular Ozone Injection on Degenerative Knee Cartilage in Rats. *Int J Ozone Ther*. 2010;9(1):14–20.
27. Paoloni M, Di Sante L, Cacchio A, Apuzzo D, Marotta S, Razzano M, et al. Intramuscular oxygen-ozone therapy in the treatment of acute back pain with lumbar disc herniation: a multicenter, randomized, double-blind, clinical trial of active and simulated lumbar paravertebral injection. *Spine*. June 1, 2009;34(13):1337–44.
28. Steppan J, Meaders T, Muto M, Murphy K. A metaanalysis of the effectiveness and safety of ozone treatments for herniated lumbar discs. *J Vasc Interv Radiol*. 2010;21(4):534–48.
29. Bocci V. [General mechanisms of action of ozonotherapy and pain related mechanism]. *Rev Esp Soc Dolor*. 2005;12(II):24–36.
30. Bocci V. *Ozone: A new medical drug* [Internet]. Netherlands: Springer; 2005. 295 p. p. Retrieved from: <http://www.springer.com/biomed/book/978-1-4020-3139-7>
31. López-Laserna Ruiz J. Results of Conservative Treatment of Tarsal Tunnel Syndrome: Medical Ozone Infiltration and Surgery. *Revista Española de Ozonoterapia*. Complutense University of Madrid, Spain: AEPRIMO; 2012. p. 62–62.
32. García-González B, García-Muñoz W, Játiva-Silvestre F. Infiltraciones locales en Cirugía Ortopédica y Traumatología. *Manual de Cirugía Ortopédica y Traumatología - SECOT*. 2ª ed. Madrid: Editorial Médica Panamericana; 2010. p. 334–42.
33. Gjonovich A, Giroto L, Sattin G, Giroto T, Preciso G. [Oxygen-Ozone Therapy in Shoulder Pain: Clinical Experience]. *Riv Ital Ossigeno-Ozonoterapia*. 2002;1(1):37–40.
34. Moretti B, Lanzisera R, Sisti GL, Moretti L, Patella S, Patella V, et al. O₂-O₃ therapy in tendinopathies and entrapment syndromes. *Riv Ital Ossigeno-Ozonoterapia*. 2005;4(1):20–9.
35. De Lucas J. [Ozone peripheral infiltration. Indications, techniques and clinical experience]. *Rev Esp Soc Dolor*. 2005;12(II):37–47.
36. Moretti M. Can Oxygen–Ozone Injections in Sport Overuse Tendinopathies Be a Valid Alternative to Cortisone Therapy? *Int J Ozone Ther*. 2010;9(1):21–4.
37. Moretti M. Effectiveness of Oxygen-Ozone and Hyaluronic Acid Injections in De Quervain’s Syndrome. *Int J Ozone Ther*. April 2012;11(1):31–3.

38. Trenti G, Gheza G. [Efficacy of Oxygen-Ozone Pain Therapy Associated with Shock Waves to Treat Calcifying Tendinitis of the Shoulder]. *Riv Ital Ossigeno-Ozonoterapia*. 2002;1(1):45–50.
39. Benvenuti P. Oxygen-Ozone Treatment of the Knee, Shoulder and Hip. *Riv Ital Ossigeno-Ozonoterapia*. 2006;5(2):135–44.
40. Ikonomidis S, Caralambus D, Vakirtzian L, Iliakis E. [Nonoperative Treatment of Shoulder Impingement Syndrome with Topical Injections of Medical Oxygen-Ozone Mixture. A double blind clinical trial.]. *Riv Ital Ossigeno-Ozonoterapia*. 2002;1(1):41–4.
41. Bonetti M. Oxygen-ozone therapy vs epidural steroids injections - CT evaluation. *Rivista Di Neuroradiologia*. 2000;13(2):203–6.
42. Baeza-Noci J. Ozonoterapia intrarticular en la gonartrosis. II Curso Teorico ACEOOT. Jerez de la Frontera; 2006.
43. Huanqi C, Cruz M. Eficacia y seguridad del ozono intraarticular en artrosis de rodilla refractaria al tratamiento. *Rev Per Reum*. 2006;12(1):21–6.
44. Baeza-Noci J. Guideline for ozone therapy in degenerative joint diseases. II Meeting of the CFOT. Urumqi; 2008.
45. Rogelio Milanés J, Acosta Rivera W, Trinchet Ayala E, Hernández Rosales F. [The ozonotherapy/Results of the treatment in patients with symptomatic degenerative arthrosis of the knee]. *Dolor, Clinica y Terapia*. 2009;6(4):18–24.
46. Baeza-Noci J. Osteoartrosis de rodilla. Resultados de la ozonoterapia. II Congreso Nacional SEOT. Marbella; 2009.
47. Guo D, Zhang X. [Study on treatment for knee osteoarthritis by medical ozone]. *Gansu Med J*. 2010;(1):10–1.
48. Moretti M. Effectiveness of Treatment with Oxygen-Ozone and Hyaluronic Acid in Osteoarthritis of the Knee. *Int J Ozone Ther*. 2010;9(1):25–9.
49. Wang J, Zhang Y, Ma Y, Xu B, Wang Q, Yin H. [Therapeutic Effect of Low Concentration Medical Ozone on Knee Osteoarthritis]. *J Liaoning Coll Tradit Chin Med*. 2010;12(4):17–9.
50. Baeza-Noci J. Knee osteoarthritis: ozone therapy results. IV International Ozone Congress. Dehli; 2010.
51. Mishra SK, Pramanik R, Das P, Das PP, Palit AK, Roy J, et al. Role of intra-articular



ozone in osteo-arthritis of knee for functional and symptomatic improvement. *Ind J Phys Med Rehabil.* 2011;22(2):65–9.

52. Aymale CA. Ozonoterapia en patología artrósica quirúrgica de rodilla [Ozone therapy in surgical pathology of arthritic knee]. Rio de Janeiro (Brazil); 2011.
53. Baeza-Noci J. Ozonoterapia en la gonartrosis y la coxartrosis [Ozonotherapy in osteoarthritis]. Rio de Janeiro (Brazil); 2011.
54. Baeza-Noci J. Ozonoterapia en la gonartrosis y la coxartrosis. XXXIV Congreso de la SIBB. Córdoba; 2011.
55. Baeza-Noci J. Ozonoterapia en la patología de cadera del adulto. IX Congreso de la ACEOOT. Granada; 2011.
56. Baeza-Noci J. Ozone therapy in adult hip pathology. III Meeting of the WFOOT. Brescia, Italy; 2011.
57. Cabot Dalmau J. Combined Technique of Ozonotherapy and Platelet Derived Growth Factors in the Knee Osteoarthritis [Técnica Combinada de Ozonoterapia y Factores de Crecimiento en la Artrosis de Rodilla]. Hotel Great Parnassus, Cancun, Mexico: Revista Española de Ozonoterapia; 2011. p. 34–5.
58. Baeza-Noci J. Ozone and rich-platelet plasma: a good team for knee osteoarthritis. IV Meeting of the CFOT. Shenyang; 2012.
59. Zambello A, Fumagalli L, Fara B, Bianchi M. Oxygen-Ozone Treatment of Carpal Tunnel Syndrome. Retrospective Study and Literature Review of Conservative and Surgical Techniques. *International Journal of Ozone Therapy.* 2008;7(1):45–8.
60. Bocci V. Is it true that ozone is always toxic? The end of a dogma. *Toxicol Appl Pharmacol.* November 1, 2006;216(3):493–504.
61. Baeza-Noci J. [Ozone spinal infiltration. Physiopathology and mechanism of action]. *Rev Esp Soc Dolor.* 2005;12(II):18–23.
62. Scuccimarra A. [The “Laminoforaminal Technique” in Oxygen-Ozone Therapy for Lumbar Disc Herniation]. *Riv Ital Ossigeno-Ozonoterapia.* 2003;2(2):193–6.
63. Zambello A, Fara B, Bianchi M, Tabaracci G. Paravertebral Oxygen-Ozone Infiltrations: High versus Low Doses: towards the Minimum Effective Dose. *Int J Ozone Ther.* 2007;6(1):37–41.
64. Verga C. Il perché ed il come dell’ossigeno ozono nel trattamento della patologia



ortopedica. Ossigeno Ozono Terapia: Pratica medica tra certezze e prospettive terapeutiche. Sorrento; 2004.

65. Muto M, Andreula C, Leonardi M. Treatment of herniated lumbar disc by intradiscal and intraforaminal oxygen-ozone (O₂-O₃) injection. *J Neuroradiol*. June 2004;31(3):183–9.
66. Juncopilla N, Franzini M. The therapy involving the infiltration of oxygen-ozone intradiscal and interfacet. 1er Congreso de la Sociedad Española de abordajes percutaneos vertebrales. Barcelona; 1995.
67. Dall'aglio R, Gomez Moraleda M, Cardoso C, Alexandre A, Fraschini F. Biochemical and Pharmaceutical Aspects of Entrapment: the Possible Role of Free Radicals and Ozone in Nerve Root Compression. *Riv Ital Ossigeno-Ozonoterapia*. 2004;3(2):105–11.
68. Murga M. [Ozone spinal infiltration. Indications, techniques and clinical experience]. *Rev Esp Soc Dolor*. 2005;12(II):10–7.
69. Leonardi M. [Disc Puncture under Fluoroscopic Guidance]. *Riv Ital Ossigeno-Ozonoterapia*. 2002;1(1):73–8.
70. Andreula CF, Simonetti L, De Santis F, Agati R, Ricci R, Leonardi M. Minimally invasive oxygen-ozone therapy for lumbar disk herniation. *AJNR Am J Neuroradiol*. May 2003;24(5):996–1000.
71. He X, Yu Z, Teng G, Li Y, Zeng Q, Chen Y, et al. [Treatment of lumbar disc herniation by using percutaneous intradiscal and paraspinal space injection of O₂-O₃ mixture]. *Chin J Radiol* [Internet]. 2003;(9). Retrieved from: http://en.cnki.com.cn/Article_en/CJFDTOTAL-ZHGS200309018.htm
72. Buric J, Molino Lova R. Ozone chemonucleolysis in non-contained lumbar disc herniations: a pilot study with 12 months follow-up. *Acta Neurochir Suppl*. 2005;92:93–7.
73. He XF, Yu ZJ, Li YH, Lu W, Zeng Q, Chen Y, et al. Percutaneous injection of intradiscal and paraspinal space with O₂-O₃ mixture to treat lumbar disc herniation. *Riv Ital Ossigeno-Ozonoterapia*. 2003;2(2):135–8.
74. He X, Li Y, Chen H, Lu W, Chen Y, Zeng Q, et al. Intradiscal injection of O₂-O₃ to treat lumbar disc herniations: clinical therapeutic effect analysis with 600 cases. *Chin J Intervent Imaging Ther* [Internet]. 2005;2(5). Retrieved from: http://en.cnki.com.cn/Article_en/CJFDTotal-JRYX200505004.htm
75. Buric J, Alexandre A, Corò L, Azuelos A. [Intradiscal Ozone Treatment of Non-Contained Disc Herniations. 18 Months Follow-up]. *Riv Ital Ossigeno-Ozonoterapia*. 2003;2(2):153–60.



76. Wang J, Li H, Wang G. [Studies on the concentration of oxygen-ozone in percutaneous intradiscal oxygen-ozone-injection for the treatment of lumber disc herniation]. *Chin J Spine Spinal Cord* [Internet]. 2007;(11). Retrieved from: http://en.cnki.com.cn/Article_en/CJFDTOTAL-ZJZS200711010.htm
77. Paradiso R, Alexandre A. The different outcomes of patients with disc herniation treated either by microdiscectomy, or by intradiscal ozone injection. *Acta Neurochir Suppl*. 2005;92:139–42.
78. Bonetti M. [CT-Guided Intraforaminal Technique]. *Riv Ital Ossigeno-Ozonoterapia*. 2002;1(1):69–71.
79. Andreula C. [Lumbosacral Herniated Discs: Chemodiscolysis with Nucleophthysis with O₂-O₃ and Periradicular and Periganglionic Infiltration under CT Guidance Personal Experience]. *Riv Ital Ossigeno-Ozonoterapia*. 2002;1(1):79–85.
80. Andreula C. Ozone therapy. *Neuroradiology*. September 2011;53 Suppl 1:S207–209.
81. Mattozi I, Laurini G, Muzzi G, Franzini M, Bigiotti A. Intrasacral epidural injection with oxygen-ozone for the treatment of low back pain. Comparison and evaluation with other techniques and rehabilitation and return to work. *European Journal of Clinical Investigation*. 2003;(33 (suppl. 1)):45.
82. Morales E. [Peridural ozone therapy in disc-radicular conflict and lumbosciatalgia]. *Jornadas Científicas SEOT 2012*. Valencia; 2012.
83. Baeza-Noci J. Spinal ozone therapy - state of the art. *Congreso Nazionale FIO*. Bologna; 2007.
84. Baeza-Noci J. Rational use of ozone therapy in degenerative spinal pathologies. 6th European Course “Minimally invasive surgery of the spine.” Treviso; 2008.
85. Baeza-Noci J, Kumar V. P429: Ozone discectomy (ozonucleolysis) for discogenic radiculopathy arising from disc herniation: one year follow-up study from Indian and Spanish centres. *Spineweek*. Geneva; 2008.
86. Baeza-Noci J. Ozone Therapy in the Musculo-Skeletal Pathology: Spine. III Meeting of the WFOOT. Brescia, Italy; 2011.
87. Bonetti M. [CT-Guided Oxygen-Ozone Infiltration into Isthmic Lysis Points in the Management of 1st Degree Spondylolisthesis and Spondylolysis]. *Riv Ital Ossigeno-Ozonoterapia*. 2003;2(1):31–8.
88. Bonetti M, Fontana A, Albertini F. CT-guided oxygen-ozone treatment for first degree



spondylolisthesis and spondylolysis. *Acta Neurochir Suppl.* 2005;92:87–92.

89. Bonetti M, Cotticelli B, Richelmi P, Valdenassi L. [Rofecoxib and O₂-O₃ Therapy vs O₂-O₃ Therapy in the Management of Spondylarthrosis]. *Riv Ital Ossigeno-Ozonoterapia.* 2002;1(2):171–8.
90. Bonetti M, Fontana A, Mardighian D. Oxygen-ozone therapy for degenerative spine disease in the elderly. *Riv Ital Ossigeno-Ozonoterapia.* 2006;5(1):25–32.
91. Bonetti M, Fontana A, Parodi F. Oxygen-Ozone Therapy Associated with Magnetic Bioresonance in Degenerative Arthrosis of the Spine: Preliminary Findings. *Int J Ozone Ther.* 2007;6(1):29–35.
92. Bonetti M, Fontana A, Martinelli F, Andreula C. Oxygen-ozone therapy for degenerative spine disease in the elderly: a prospective study. *Acta Neurochir Suppl.* 2011;108:137–42.
93. Baeza-Noci J. Spinal Ozone Therapy in Lumbar Spinal Stenosis. *Int J Ozone Ther.* 2007;6(1):17–24.