



## Method for Standard Operation Procedure, Clinic Procedure

### Index

Method for Standard Operation Procedure, Clinic Procedure.....	1
References: .....	2
Change History .....	2
Document Records .....	2
Attachment 1. Hypothetic example of SOP Clinical Procedure.....	3

## Method for Standard Operation Procedure, Clinic Procedure

This document provides guidance for writing a standard operating procedure (SOP) who describes clinical procedure in ozone therapy.

SOP describes methods in ozone therapy that should be included:

1. Title
  - 1.1. Brief background
  - 1.2. Purpose
  - 1.3. Scope
  - 1.4. Acronyms, abbreviations and definitions
2. Responsibility
3. Etiology
4. Anatomy
5. Diagnosis Consideration
6. Physical and complementary examinations
7. Evidences of ozone effect
8. Procedure
  - 8.1 Indications
  - 8.2 Contraindications
  - 8.3 Recommended doses intervals
  - 8.4 Clinical evaluation
  - 8.5 Preliminary operations
  - 8.6 Main procedure
  - 8.7 Alternatives



## International Scientific Committee of Ozone Therapy

Tel/Fax (+34) 913515175. Cell Phone (+34) 669685429  
Avenida Juan Andrés 60. Local 1 – Bajo Izquierdo 28035,  
Madrid (Spain) [info@isco3.org](mailto:info@isco3.org) [www.isco3.org](http://www.isco3.org)

SOP: ISCO3/QAU/00/13  
Version: 1 Draft  
Date: 05/09/2015  
Page 2 of 10

- 8.8 Frequent side effects
- 8.9 Patients Follow-up
- 9. Contingencies; Corrective Actions
- 10. References
  - 10.1 SOP References
  - 10.2 Other References
- 11. Documentation and Attachments
  - 11.1 List of recommended medical disposables
  - 11.2. Proposal Informed concert
- 12. History of Change
- 13. Document records

### References:

URL: <http://hub.ucsf.edu/sop-guidelines>

### Change History

SOP no.	Effective Date	Significant Changes	Previous SOP no.
ISCO3/QAU/00/12	05/09/2015	First version approved by ISCO3 Board	First version

### Document Records

	Name	Title	Signature	Date
Author	Gregorio Martínez-Sánchez	Elected president Ph.D.; Pharm. D.		31/08/2015
Co. Authors / Reviewer	Fadi Sabbah	Elected vice- president D.DS.		02/09/2015
	Adriana Schwartz	Elected secretary M.D.		05/09/2015
Authoriser / Approved	ISCO3 Board 2015-2020			



## Attachment 1. Hypothetic example of SOP Clinical Procedure

Note: The following is a hypothetic example of a procedure. This is not a draft under review.

### 1. Title ISCO3/CLI/00/32 Tarsal Tunnel

#### 1.1. Brief background

The tarsal tunnel syndrome (TTS) is an extrinsic or intrinsic neuropathy of the foot, secondary to compression of the tibial nerve (TN) or one of its terminal branches (medial plantar n., Lateral plantar n. Medial calcaneus n.) in the tarsal canal or channel Richet. The release thereof was first described by Keck and Lam in 1962. In the current nomenclature we speak of posterior and anterior tibial nerve, naming them as deep peroneal and tibial nerve.<sup>1</sup> This disorder is less frequent and diagnosis is far more complex than that of carpal tunnel syndrome. The etiology of posteromedial tarsal tunnel syndrome varies and the disease may affect different regions and any of the nerve branches.<sup>2</sup>

#### 1.2. Purpose

The purpose of this SOP is to describe the procedure to treat Tarsal Tunnel using infiltration of ozone.

#### 1.3. Scope

This procedure specified the diagnosis, anatomical main aspects, infiltration technique, doses, volume of gas and frequency of application of ozone Tarsal Tunnel.

#### 1.4. Acronyms, abbreviations and definitions

SOP	Standard Operation Procedure
MRI	Magnetic resonance imaging
TTS	Tarsal tunnel syndrome
TN	Tibial nerve
US	High-resolution ultrasound

### 2. Responsibility

<b>Physician</b>	Clinical records registration Assessment of the indication, contraindications Request the informed consent and the privacy consent Applications and monitoring Recording all data on medical records Prescription of investigations to assess the effectiveness of the treatment (e.g. microbiology)
------------------	---



Reporting any late complications  
Patient follow-up

**Nurses** Accommodate the patients  
Preparation of the clinical procedure  
Supervision of patients, and vital signs control (temperature and pressure)  
Detects and alerts the doctor to anomalies due to possible reactions  
Notification of possible complications

### 3. Etiology

Tarsal tunnel syndrome occurs for numerous reasons; the frequency of the different etiologies varies in the literature and a compression element is detected between 60 and 80 %. Tarsal tunnel syndrome may be caused by idiopathic conditions or for traumatic reasons (bone diseases, injuries to the ligament, thickening of the flexor retinaculum, hematoma, fibrosis, and iatrogenic damage to the nerves), tendon disorders (tendinopathy and flexor tenosynovitis), supernumerary muscles (accessory soleus muscle, medial fibulocalcaneal muscle, and particularly accessory flexor digitorum muscle) or muscle hypertrophy (abductor hallucis muscle or flexor hallucis muscle of the toes).

The syndrome may be caused also by bone disorders (talocrural and subastragalar arthritis and arthropathy with talocalcaneal synovitis and synostosis, sustentaculum tali, sequelae of fracture, change in static foot posture), expansive lesions (ganglion cysts, particularly epineural ganglions, soft tissue tumors including intracanal lipomas and tumors of the nerves), vascular disorders (kinking of the tibial artery, venous aneurysms, and varicose plantar veins particularly in the distal tarsal tunnel, which is commonly reported in the literature).<sup>2</sup>

### 4. Anatomy

The tarsal tunnel is a fibrous osseous tunnel situated posteriorly and inferiorly to the medial malleolus, and it presents a proximal and a distal floor. The proximal retromalleolar floor is limited by the flexor retinaculum and contains the flexor tendons, the posterior tibial tendon, the flexor digitorum longus, the flexor hallucis longus, and the tibial neurovascular bundle (Fig. 1). The distal floor is located below the malleolus, at the medial plantar side. It lies between the abductor hallucis muscle and its arch, which are located superficially, and the deep quadratus plantae muscle. The distal portion contains branches of the plantar vessels and tibial plantar nerves.

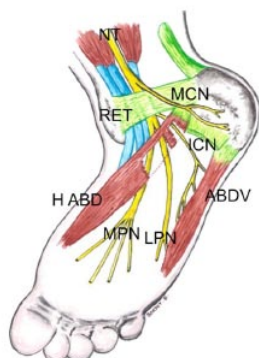


Fig. 1. Schematic anatomy of the tarsal tunnel located below the flexor retinaculum (RET) and under the abductor hallucis muscle (H ABD). The tibial nerve (NT) gives rise to a collateral branch, the medial calcaneal nerve (MCN), which is superficial, before it divides into two terminal branches: the medial plantar nerve (MPN) and the lateral plantar nerve (LPN). The inferior calcaneal nerve (ICN) also referred to as the motor branch to the abductor muscle of the fifth toe (ABD V) arises from the lateral plantar nerve at the level of division of the tibial nerve. It travels under the abductor hallucis muscle and under the arch.<sup>2</sup>

## 5. Diagnosis Consideration

Diagnosis is established on the basis of physical examination and can be confirmed by electrophysiological evidence. However, diagnostic imaging is always required to identify the site of compression. Magnetic resonance imaging (MRI) is a valid technique for assessing the peripheral nerves, including those in the tarsal tunnel,<sup>3,4</sup> but high-resolution ultrasound (US) is playing an increasingly important role in the study of the nerves thanks to several advantages.<sup>2</sup>

## 6. Physical and complementary examinations

Patients with this disorder present with pain, paresthesia, hypoesthesia, hyperesthesia, muscle cramps or numbness affecting the heel and/or the sole of the foot, and the symptoms may spread to the toes. The location of the symptoms may suggest which nerve branch is affected. Pain in the heel or ankle suggests that the medial calcaneal nerve and the motor branch abductor of the fifth toe are affected. Pain in the medial border of the foot and medial toes suggests that the medial plantar nerve is affected, whereas pain in the lateral border of the foot and the lateral toes suggests that the lateral plantar nerve is affected.<sup>3</sup>

These symptoms mainly occur while walking, during exercise, and at night when the patient is at rest. The movements of dorsiflexion and eversion of the foot can also cause the symptoms.<sup>4</sup> The US Tinel sign may be detected using prolonged pressure or tapping with the probe. The symptoms can be reproduced by applying local compression using a tourniquet for the measurement of pressure, thereby increasing the local venous pressure and causing local ischemia.<sup>4</sup> In severe cases, there may be motor involvement, such as loss of power during plantar or toe flexion.



Physical examination may also reveal a possible deformity of the foot such as varus or valgus deformity, which may cause pain while the patient is at rest and during walking due to stretching of the nerve.<sup>3</sup> Tarsal tunnel syndrome is one of the most common causes of heel pain. If US imaging does not reveal a “classic” etiology, typically an inflammatory condition of the plantar fascia, the tarsal tunnel should be explored. The foot may also be affected by a combination of disorders involving the plantar fascia and the motor branch abductor of the fifth toe as this condition is the cause of 15–20 % of cases of heel and/or ankle pain in young patients.<sup>5</sup>

Electromyography is always carried out to evaluate the function of the nerves. However, a negative outcome does not exclude possible disorders. Electromyography furthermore allows detection of polyneuritis and radicular neuropathy. In posteromedial tarsal tunnel syndrome, the diagnostic procedure begins with a traditional X-ray examination for the detection of possible static foot disorders and bone injuries caused by fractures, exostosis or talocalcaneal synostosis. The patient should be referred to MRI and US imaging only after X-ray examination.

## 7. Evidences of ozone effect

Level of evidence: Level B (according to the definition of Madrid Declaration ISCO3/QAU/01/03).

Evidence: Dr. López-Laserna Ruiz, Juan (Spain)<sup>1</sup> Since 1999 have treated 588 TTS, with systematically performed a thorough examination, studies Rx laden feet, and in cases not cured with injections of medical ozone (MO), EMG, ENG, NMR, etc. All patients have been treated by the same medical team and those who have been cured of their symptoms with the infiltration of TTS (not associated pathologies) have been treated surgically. As we have made treatment regimen TTS infiltration fortnightly up to 3, with 2 % mepivacaine without epinephrine, we have waited three minutes to inject 10 mL medical ozone at a concentration of 30 µg/ mL.

Cured by MO 490 infiltration TTS, 10% with the first, 30% with the second and 40% in the third. The remaining 20% were treated surgically. Dr. Laserna have intervened 98 TTS in 84 patients by 2% of our interventions in pathologies of the foot, in this period he have operated in his Unit 6 240 feet. The results have been excellent, 80% good in 18% and he just had two bad results. The TTS is a common foot, the results with OM infiltration lead to cure in 80% of cases. In the remaining patients either performed surgical treatment gives excellent results.<sup>1</sup>

## 8. Procedure

### 8.1 Indications

Tarsal tunnel syndrome.

### 8.2 Contraindications



## International Scientific Committee of Ozone Therapy

Tel/Fax (+34) 913515175. Cell Phone (+34) 669685429  
Avenida Juan Andrés 60. Local 1 – Bajo Izquierdo 28035,  
Madrid (Spain) [info@isco3.org](mailto:info@isco3.org) [www.isco3.org](http://www.isco3.org)

SOP: ISCO3/QAU/00/13  
Version: 1 Draft  
Date: 05/09/2015  
Page 7 of 10

Patients fit any of the contraindication to ozone therapy (ISCO3/QAU/01/03).

### 8.3 Recommended doses intervals

Concentrations of 30  $\mu\text{gN/mL}$  with a volume of 2.5 mL per point to infiltrate. Tres sessions are required (one every 15 days).<sup>1</sup>

### 8.4 Preliminary operations

The practitioner will be well trained in this method.

Fill all medical records of the patient, get the informed consent (ISCO3/QAU/00/21) and the privacy consent.

Make the appropriate diagnose and verify the indication and contraindication.

Prepare the appropriate dose of ozone using and adequate device ISCO3/DEV/00/01.

Ask to the patient to discover the affected area.

Clean the area with antiseptic solution

### 8.5 Clinical evaluation

Using a tongue depressor and appropriate medical lamp and magnifying glass, check the tonsil

### 8.6 Main procedure

Apply a cool spay of anesthetic.

Infiltrate 0.5 mL of mepivacaine 2% without epinephrine.

Waite three minutes.

Infiltrate 10 mL medical ozone at a concentration of 30  $\mu\text{g/ mL}$ .

Apply a massage in the treated area.

### 8.7 Alternatives

Not applicable.

### 8.8 Frequent side effects

Local pain.

### 8.9 Patients Follow-up

Check the patients every 15 days.

## 9. Contingencies; Corrective Actions

In case of incidental  $\text{O}_3$  inhalation follow procedure ISCO3/CLI/00/01.



## International Scientific Committee of Ozone Therapy

Tel/Fax (+34) 913515175. Cell Phone (+34) 669685429  
Avenida Juan Andrés 60. Local 1 – Bajo Izquierdo 28035,  
Madrid (Spain) [info@isco3.org](mailto:info@isco3.org) [www.isco3.org](http://www.isco3.org)

SOP: ISCO3/QAU/00/13  
Version: 1 Draft  
Date: 05/09/2015  
Page 8 of 10

## 10. References

### 10.1 SOP References

ISCO3/DEV/00/01 Guidelines and Recommendations for Medical Professionals Planning to Acquire a Medical Ozone Generator.

ISCO3/QAU/01/03. Madrid Declaration on Ozone Therapy 2015-2020 Eng. Schwartz-Tapia A, Martínez-Sánchez G, Sabah F, Alvarado-Guómez F, Bazzano-Mastrelli N, Bikina O, Borroto-Rodríguez V, Cakir R, Clavo B, González-Sánchez E, Grechkanov G, Najm Dawood A H, Izzo A, Konrad H, Masini M, Peretiagyn S, Pereyra, V R, Ruiz Reyes D, Shallenberger F, Vongay V, Xirezhati A, Quintero-Marino, R. **Madrid Declaration on Ozone Therapy**. 2th ed. Madrid: ISCO3; ISBN 978-84-606-8312-4; 2015. 50 p.

ISCO3/QAU/00/21. Informed Consent Form in Ozone Therapy.

ISCO3/CLI/00/01. Fist Aids in ozone therapy (Inhalatory exposition and accidental over dose)

### 10.2 Other References

1. López-Laserna Ruiz, Juan. «Results of Conservative Treatment of Tarsal Tunnel Syndrome: Medical Ozone Infiltration and Surgery.» En *Revista Española de Ozonoterapia*, 2:62-62. 2. Complutense University of Madrid, Spain: AEPROMO, 2012.
2. Fantino O. Role of ultrasound in posteromedial tarsal tunnel syndrome: 81 cases. *J Ultrasound*. 2014 Mar 28;17(2):99-112. doi: 10.1007/s40477-014-0082-9. eCollection 2014.
3. Bouysset M, Coury F, Labarre-Vila A, Damiano J, Gerbay B, Tebib J (2012) Considérations sur le syndrome du canal tarsien postéromédial et les formes apparentées (lésions du nerf tibial et de ses branches). *Me´d Chir Pied* 28:69–72
4. Lau JT, Daniels TR (1999) Tarsal tunnel syndrome: a review of the literature. *Foot Ankle Int* 20:201–209
5. Demondion X (2011) Anatomie normale des nerfs du pied, les sièges du conflit. In: *Le pied, GETROA-GEL OPUS XXXVIII*. Sauramps Me´dical, Montpellier p 243–52

## 11. Documentation and Attachments

### 11.1 List of recommended medical disposables

Needle 27 G (0.4) or 30 G (0.3 mm) x 3/4 (20 mm).  
Siliconated Luer lock syringe of 5 mL

### 11.2 Proposal of Informed concert





**International Scientific Committee of  
Ozone Therapy**

Tel/Fax (+34) 913515175. Cell Phone (+34) 669685429  
Avenida Juan Andrés 60. Local 1 – Bajo Izquierdo 28035,  
Madrid (Spain) [info@isco3.org](mailto:info@isco3.org) [www.isco3.org](http://www.isco3.org)

SOP: ISCO3/QAU/00/13  
Version: 1 Draft  
Date: 05/09/2015  
Page 9 of 10

**Informed Consent Form in Ozone Therapy in the treatment of tarsal tunnel**

Mr./Miss. \_\_\_\_\_ Surname: \_\_\_\_\_ Name: \_\_\_\_\_  
Place of Birth: \_\_\_\_\_ Date of Birth \_\_\_\_\_ / \_\_\_\_\_ / \_\_\_\_\_  
(dd/mm/yy):  
Resident \_\_\_\_\_  
Identity Number \_\_\_\_\_ Phone \_\_\_\_\_  
Health care center: \_\_\_\_\_

- a) Pathology: tarsal tunnel
- b) Therapeutic alternatives related to the symptoms presented by the patient: surgical intervention or injection with steroidal anti-inflammatory
- c) Medical or surgical treatment that you will apply (explain why and what you want to achieve): local injection of anesthetic an ozone to reduce local pain and obtain an anti-inflammatory effect.
- d) Procedure before apply the main treatment: clean the affected area and application of local cool spay
- e) Main Procedure (what will be done and how long): Local application of ozone for a few minutes
- f) Possible treatments or interventions that may be necessary in addition to the main treatment: first aids in case of incident
- g) Complications: local reaction to ozone gas, eritema or local pain for a few minutes
- h) Adverse effects that may manifest after therapy: low local pain.
- i) Therapy or directions you need to follow after the main intervention: follow-up every 15 days, tree times

The undersigned (taking into consideration as described above, with full awareness and freedom)

**DECLARES**

- ✓ Be fully aware,
- ✓ Having carefully read the entire document,
- ✓ That the doctor who carried out the treatment has explained everything to my full understanding of what has been stated in the document,
- ✓ To have fully understood the content of the document,
- ✓ Authorize the executor doctor to make the surgical / medical treatment described above,
- ✓ I can stop treatment at any time,
- ✓ What can be compensated as a result of the procedure if unforeseen or unexpected injuries was originate,
- ✓ Authorize from this moment the procedure described in item f).

Date (dd/mm/yy) \_\_\_\_\_ / \_\_\_\_\_ / \_\_\_\_\_ Patient signature\* \_\_\_\_\_  
\* Representative or guardian (if the patient does not cooperate or is a minor).

**Declaration of the physician in charge to inform the patient.**

The undersigned Dr. \_\_\_\_\_ confirm and attest, by signing this document, which it, in my opinion, has been understand in full, point by point, by the patient.

Date (dd/mm/yy) \_\_\_\_\_ / \_\_\_\_\_ / \_\_\_\_\_ Physician signature\* \_\_\_\_\_  
\* All previously reported herein provides a synthetic information about the procedure and its function does not replace the doctor / patient dialogue.



## International Scientific Committee of Ozone Therapy

Tel/Fax (+34) 913515175. Cell Phone (+34) 669685429  
Avenida Juan Andrés 60. Local 1 – Bajo Izquierdo 28035,  
Madrid (Spain) [info@isco3.org](mailto:info@isco3.org) [www.isco3.org](http://www.isco3.org)

SOP: ISCO3/QAU/00/13  
Version: 1 Draft  
Date: 05/09/2015  
Page 10 of 10

### 12. Change History

SOP no.	Effective Date	Significant Changes	Previous SOP no.
ISCO3/MET/00/17	1/09/2015	Draft. Especial edition as methodological example	First version

### 13. Document Records

	Name	Title	Signature	Date
<b>Author</b>	Gregorio Martínez-Sánchez	Elected president Ph.D.; Pharm. D.		1/09/2015
<b>Co. Authors / Reviewer</b>	Fadi Sabbah	Elected vice- president D.DS.		xx/09/2015
	Adriana Schwartz	Elected secretary M.D.		xx/09/2015
	Juán López-Laserna Ruiz	Expert committee member ISCO3. M.D.		xx/09/2015
<b>Authoriser / Approved</b>	ISCO3 2015-2020 All members.			